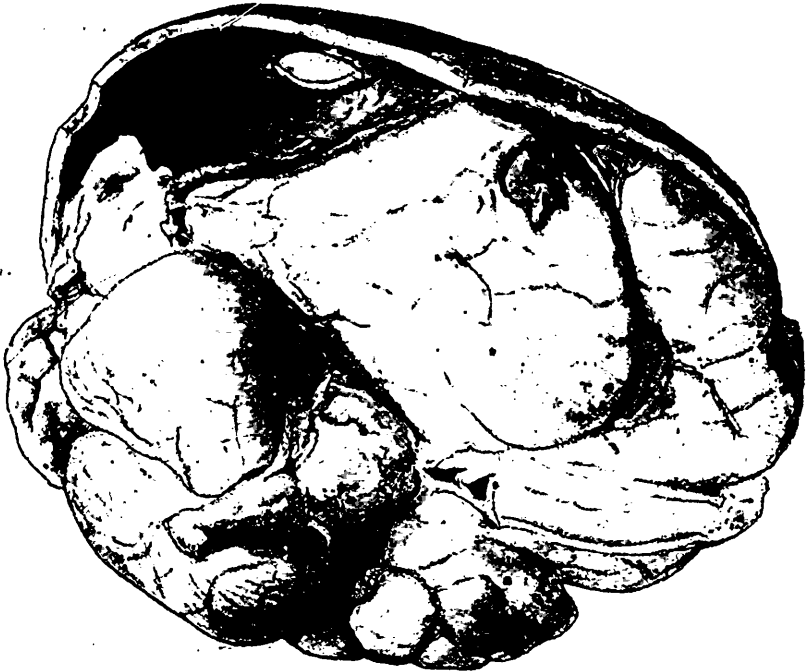


police ambulance, with an incomplete history of having been injured by the street railway the day before. A complete history of injuries was not ascertained till a few hours before his death.

He was examined hurriedly by Dr. McCauley and myself while waiting to be admitted. We found that the left arm was completely paralyzed, but that there was an incomplete paralysis of the left leg, inasmuch as he was able to move the leg and knee



Specimen of brain in skull-cap showing depressed brain, separated dura mater, trephine openings and hemorrhage into right temporo-sphenoidal lobe.

slightly, and as he resisted Dr. McCauley in his manipulation of the leg. His eyes were closed and the breathing was stertorous. There was inequality of the pupils.

He was sent up to the ward and I examined him about twelve o'clock. The patient was a heavy set, well-nourished man about five feet ten inches in height, weighing about 190 pounds, iron grey whiskers and hair. He lay with eyes closed and breathing in a stertorous manner. He had no control of