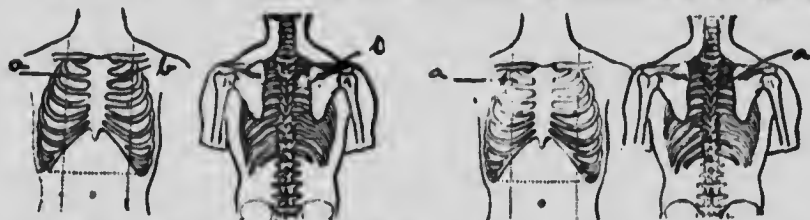
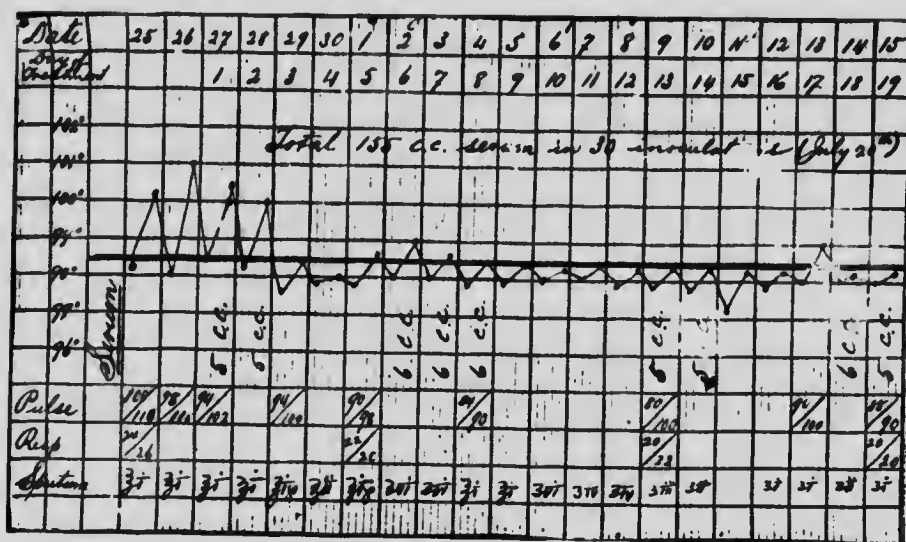


diseases of childhood, whooping-cough, measles, chicken-pox. Family history negative. Three years ago this patient had an ischio-rectal abscess, which was then opened, but left a fistula which still discharges. He has had two small abscesses in the same region since, which broke of themselves. This patient had a pretty profuse hæmorrhage about fifteen months since, which kept him in bed for about three weeks. He was gradually allowed to work, and evidently did not always feel up to his task, for he consulted a physician in his own country (Ireland) in March, and this physician advised that he should come to Canada



CASE III. FIG. 4.—a. Fibroid condition; b., disseminated condition. Left figures, April 27th, 1901. Right figures, July 11th, 1904.



CASE III. CHART 4.

in order to regain his health. The condition shown on his chart shows well the extent of the old fibrous lesion and also the more recent infiltration of a disseminated nature; but in addition to that the effects of beginning infiltration in the left lung are also shown. At the present time he still has a few bacilli in his expectoration, which, by the way, as will be noted, has diminished from one ounce to about half a dram in the twenty-four hours, while the