

appearance was that shown in Plate II. At the present time the condition is most satisfactory, there being a smooth supple cicatrix present.

The second case was in a man of 39, referred by Dr. Baldwin, Benito, Manitoba. Five years ago an ulcer developed above the right eyebrow. With the exception of ointments no treatment was received for three years. During the last two years he had received treatment with carbonic acid snow, and had one application of the X-ray. The appearance is seen in Plate III; the ulcer being one and one-half inches in diameter, and extending down to the bone. The edges were much thickened. A heavy radium exposure was given, following which healthy granulations

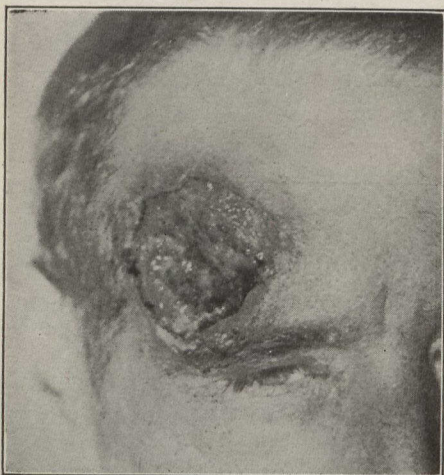

Plate III. Rodent ulcer of forehead, present for 5 years.




Plate IV. Healing produced by the use of radium on case illustrated in Plate III.

formed and gradual cicatrization took place. Plate IV shows the appearance at the present time. Complete healing has occurred.

*Epithelioma of the Skin.*—Radium used on squamous-celled epithelioma of the skin gives excellent results. Depending on the depth of involvement slight variations must be made as regards the length of application; screening the apparatus, etc. Where there is a good deal of thickening of the edge of the ulcer, or it tends to be fungating, preliminary curettage hastens the cure, the radium plaques being applied a few hours later. Prolonged exposures using heavily screened apparatus which emits only the harder beta and gamma rays, should be given, and healing takes