

II. THE RADICAL CURE OF VARICOCELE.

The indications for operating on varicocele that I have met with have been six.

1. For producing mental disturbance. Two cases of this nature came to me for treatment, one a farmer and the other a laborer. Both were mentally troubled, and even depressed, at the thought of becoming impotent and sterile. There was but slight enlargement of the left spermatic veins in both cases, which they thought was produced by masturbation. One of them intended to get married, and wishing to be cured before doing so consulted two medical men, who made so light of the trouble that distressed his mind for a number of years, that he came to the conclusion that they knew nothing about his particular case, and was even more discouraged than ever.

The other had read quack pamphlets and was worked up to a high pitch of excitement lest he should become insane. He was preparing to go to Pierce's establishment in Buffalo, to be treated in a new and special manner hitherto unknown in surgery. Could it have been possible to allay the mental worry in these cases no operation would have been necessary; but failing to do this I removed the offending veins with the result of curing the mind as well as the varicocele. It is now over two years since, and they are both in the same neighborhood contented, healthy and happy.

2. The second indication for excising the veins was in a person whose varicocele returned to be worse than ever after being subcutaneously ligatured four years previously by a Guelph surgeon. There was a constant ache unrelieved by a suspender. He was cured by operation.

3. The third necessity for operating was the large size; the inconvenience and discomfort accompanying it. I have relieved four cases of this class by operation.

4. A fourth condition demanding operation was in the case of a constable from Regina, sent to me in July last, by Dr. Dodd, Surgeon to the N. W. M. P. His

varicocele, though not large, still incapacitated him from active service. He attributed it to riding on horse back day after day, and tells me that a great number of the mounted policemen are troubled in the same way. The accompanying figures 1 and 2 represent



Fig. 1.

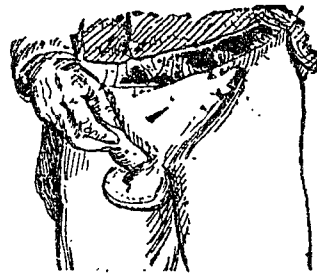


Fig. 2.

this case before and six days after operation. In the photograph taken by Dr. Todd, house surgeon, the line of incision was not noticeable, coaptation being so accurate, after union by first intention, consequently the engraver was directed to show it by a small line in fig. 2.

5. I have only met with one case in which atrophy of the testicle was produced by varicocele. In this case it was present since sixteen years of age, and ever since (15 years ago) the testicle has not developed equal to the opposite one, and the last couple of years he fancied it was growing less. I operated on him last February, have heard from him that he is suffering no pain, and cured, but I have not seen him.

6. A sixth indication, and one I have not noticed given by any other surgeon, in reviewing the literature on the subject,