

habit of occupation two other questions must be settled: Has occupation directly caused rupture of the infarct, or at least has it prevented the proper healing of it? To-day we are in the habit of dismissing such questions from our thoughts in the

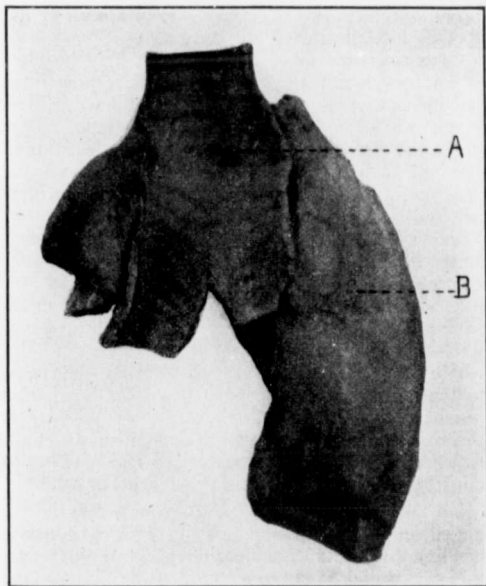


FIG. 2.—Same as Fig. 1, from the tracheal side. *A*, perforation into the trachea; *B*, gelatinous, thickened adventitia of aorta.

study of individual cases, as being of no practical bearing on the case or being uncertain. But, properly collected and critically accumulated, such factors may acquire a very great importance regarding the origin and termination of the disease,