

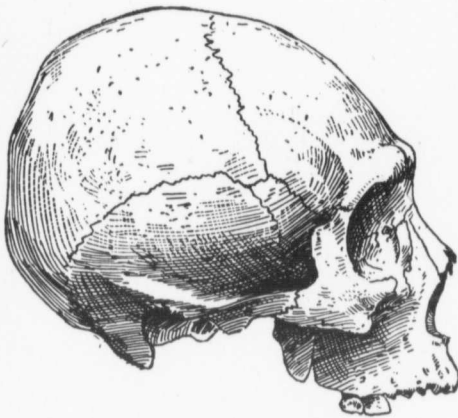Fig. 128. C. (Brit. Columbia.)

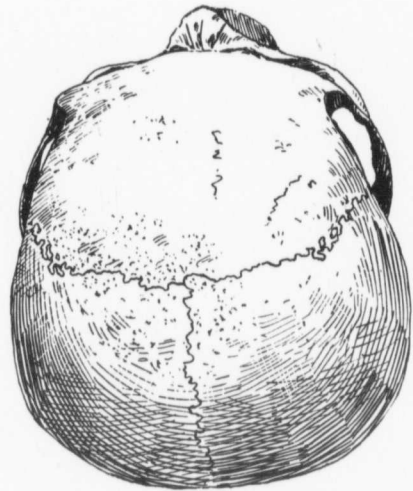


Fig. 129. C. (Brit. Columbia.)

*Cranioscopy.**Craniometry.*

		Millimetre.
Age, 30.....	1	170
Sex, male.....	2	159
Sutures, lambdoid takes an irregular course ..	3	126
Pterion, H, bridge very narrow.....	4	100
Artificially lengthened occipital foramen, O.	5	109
Lateral parietes, very full.....	6	117
Glabella, very prominent.....	7	15
Superciliary ridges, medium.....	8	105
Forehead, retreating.....	9	110
Frontal eminences, absent.....	10	60
Inion, 1.....	11	52
Probola, flat.....	12	320
Sub-iniac curve, extends below condyles.....	13	232
Mastoid process, small pointed.....	14	286
Wormian bones, five present. A small one at	15	518
posterior termination of sagittal suture.	16	98
One large and two small in lambdoid suture	17	146
on right side, and a small one just above	18	56
mastoid region in left lambdoid.....	19	25
Hollow at root of nose, shallow.....	20	90.3
Inferior border nares, curves run sharply up-	21	62.2
ward and outward.....	22	91.7
	23	74.1

See page 60 for Key to Measurements.